

Hemolytic anemia caused by hereditary pyruvate kinase deficiency in a West Highland White Terrier dog

Anemia hemolítica causada por la deficiencia de piruvato quinasa hereditaria en un perro West Highland White Terrier

NRC Hlavac^a, LA Lacerda^{a*}, FO Conrado^b, PS Hünning^a, M Seibert^c, FHD González^d, U Giger^e

^aPostgraduate Program in Veterinary Sciences, Universidade Federal Rio Grande do Sul, Porto Alegre, RS, Brasil.

^bVeterinary Clinic Pathology, Universidade Federal Rio Grande do Sul, Porto Alegre, RS, Brasil.

^cClinic Pathology, PetLab Ltda, Porto Alegre, Brasil.

^dDepartment of Veterinary Clinic Pathology, Faculty of Veterinary, Universidade Federal Rio Grande do Sul, Porto Alegre, RS, Brasil.

^eLaboratory of Genetic Diseases, University of Pennsylvania, Philadelphia, United States.

RESUMEN

La deficiencia de piruvato quinasa (PK) es un desorden hemolítico autosómico recesivo descrito en perros y gatos. La piruvato quinasa es una de las enzimas regulatorias esenciales de la glicólisis anaeróbica, la deficiencia de esta enzima causa una destrucción prematura de los eritrocitos. El presente es un estudio de caso y relata los hallazgos clínicos y paraclínicos en un perro brasileño de la raza West Highland White Terrier (WHWT) con historia de debilidad e intolerancia al ejercicio. El paciente presentaba mucosas pálidas, anemia hemolítica bastante regenerativa y osteoclerosis. La deficiencia de PK fue confirmada a través de una prueba de ADN raza específica para la inserción 6bp en el extremo 3' del exón 10 de la secuencia del gen de la piruvato quinasa eritrocitaria (R-PK) como fue descrito. Al perro se le practicó eutanasia a los 20 meses de edad debido al deterioro de su estado clínico, el cual incluyó anemia e incompatibilidad sanguínea. En otros casos descritos en perros de la raza WHWT con esta deficiencia, existen relatos hasta de nueve años de sobrevivencia. Los defectos hereditarios deben ser objeto de diagnóstico diferencial importante en casos de anemias hemolíticas crónicas en animales jóvenes después de la exclusión diagnóstica de disturbios inmunomediados y causas infecciosas. Adicionalmente, perros de razas puras para las cuales la prueba de ADN está disponible para enfermedades hereditarias deben ser evaluados antes de la edad reproductiva para limitar la diseminación del alelo mutante y la generación futura de animales deficientes.

Key words: pyruvate kinase, erythroenzymopathies, genetic disease, regenerative anemia.

Palabras clave: piruvato quinasa, eritroenzimopatías, enfermedades genéticas, anemia regenerativa.

INTRODUCTION

The natural occurrence of hereditary blood disorders in animals provides a unique opportunity to study the biochemical and molecular pathogenesis of these diseases and to investigate possible therapeutic options (Giger *et al* 2006, Sewell *et al* 2007).

Several hereditary erythrocytic disorders that cause hemolytic anemia and additional unique features have been described in dogs and cats, including membrane defects and enzyme deficiencies; however, interestingly enough no hemoglobinopathies have been discovered in companion animals. Enzyme deficiencies may involve: 1) heme synthesis causing porphyria in cats (Clavero *et al* 2010^{a,b}), 2) heme reduction by methemoglobin reductase causing cyanosis, and (Harvey *et al* 1991) 3) glycolytic

erythroenzymopathies. If either pyruvate kinase (PK) or phosphofructokinase (PFK), the two key regulatory enzymes in anaerobic glycolysis, is deficient, erythrocytic ATP production will be impaired and red blood cells (RBCs) will have a shortened survival. Pyruvate kinase deficiency is the most common erythroenzymopathy in humans, dogs and cats. In dogs, PK deficiency causes a severe chronic and highly regenerative hemolytic anemia with progressive osteosclerosis, while in cats it is characterized by an intermittent hemolytic anemia without osteosclerosis. Pyruvate kinase deficiency has been previously described in the Basenji, Beagle, West Highland White Terrier (WHWT), Cairn Terrier, American Eskimo Dog, Poodle Toy, Chihuahua, Labrador retriever and Pug, all from the United States, and a Dachshund from Germany (Chapman and Giger 1990, Giger and Noble 1991, Whitney and Lothrop 1995, Kohn *et al* 1999, Skelly *et al* 1999, Harvey 2006, Harvey 2010, Giger 2010).

This case report describes the clinical course, laboratory alterations, molecular diagnosis, and management of the first PK-deficient Brazilian WHWT dog, suggesting

Accepted: 03.11.2011.

* luciana.lacerda@ufrgs.br

the potential worldwide distribution of this disorder and that it possibly goes by under-diagnosed.

MATERIAL AND METHODS

A 19-month-old intact female WHWT dog was referred to the Veterinary Teaching Hospital at the Universidade Federal do Rio Grande do Sul (VTH – UFRGS) for evaluation of anemia observed since puppyhood (figure 1). Historically the puppy was weak, has episodes of syncope and constantly showed pale gums on routine clinical examination. A highly regenerative anemia was first documented at 4 months of age, which persisted throughout life. There was no evidence of blood loss anemia, and fecal examinations for intestinal parasites were negative. Thus, a hemolytic anemia caused by an infection, immune-mediated process or toxicity was considered. In previous clinical visits babesiosis was suspect due to severe anemia and also giardiasis because the puppy had some episodes of loose and greenish faeces. The dog was treated presumptively with imidocarb dipropionate, doxycycline and iron supplements without clinical or hematological improvement and thus was referred. The hematological analyses prior to referral to the VTH – UFRGS were performed in private clinics.

RESULTS AND DISCUSSION

At VTH – UFRGS, a macrocytic, hypochromic anemia was detected by a hematology analyzer (ABX micros, Horiba, São Paulo) and severe reticulocytosis was detected through manual reticulocyte count (table 1). The hyperchromic anemia observed in the first VTH – UFRGS exam may be due to in vitro lysis or technical artifact. On blood smear evaluation anisocytosis, marked polychromasia, and normoblastosis were present. However, no spherocytes,

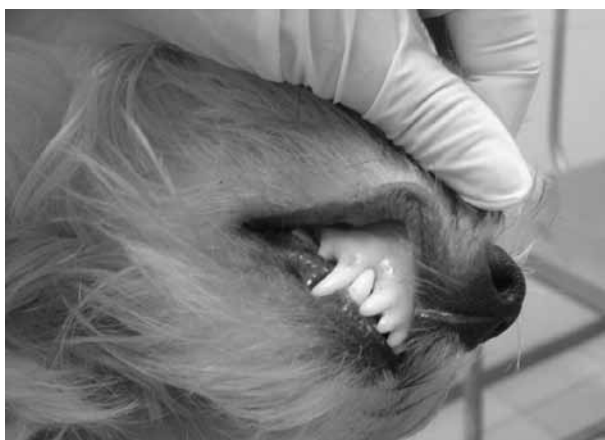

Figure 1. Pallor in 19-month-old WHWT puppy with erythrocytic PK deficiency.

Palidez en un cachorro WHWT de diecinueve meses de edad con deficiencia eritrocítica de PK.

Heinz bodies, poikilocytes or infectious agents were detected, and the direct Coombs' test was negative for IgG antibodies on RBCs. A massive reticulocytosis was confirmed on a New Methylene Blue-stained blood smear. Leukopenia and thrombocytopenia was also noted and could be explained by the possible myelofibrosis, common in dogs with this disorder (permission for a bone marrow biopsy was not received).

The clinical chemistry profile showed mild hyperbilirubinemia (0.6 mg/dL; reference value < 0.4), with no other alterations. An abdominal ultrasound examination revealed hepatosplenomegaly, and abdominal radiographs indicated mildly increased medullary bone opacity of the ischiatic bone.

Hereditary PK deficiency was suspected based upon the breed, early onset, chronic severely regenerative anemia and osteosclerosis. An EDTA blood sample was sent to the PennGen Testing Lab (University of Pennsylvania, USA) for breed specific PK mutation analysis. Briefly, DNA was extracted from nucleated cells from a small aliquot of the EDTA blood and specific primers were used to amplify the region surrounding the known mutation in WHWT with a polymerase chain reaction. The amplified segments were electrophoretically assessed for a 6 base pair in-frame insertion at 3' end of exon 10 in R-PK (RBC isoenzyme) gene previously documented in WHWT dogs. The dog reported here was found to have this same mutation thereby confirming PK deficiency.

Based upon the clinical signs and anemia a transfusion was deemed necessary. The dog had been previously transfused without blood typing and crossmatching. In order to assure a safe transfusion, compatibility testing was performed. The dog's red blood cells (RBC) were Dog Erythrocyte Antigen (DEA) 3, 4 and 5 positive, but DEA 1.1, 1.2 and 7 negative. Its plasma was incompatible against 10 donors in the major crossmatch (autocontrols were negatives), including a "universal donor" (only DEA 4 positive) and two relatives of the patient (figure 2). Thus, alloantibodies against DEA 1.1, 1.2 and 7 could be ruled out, and an alloantibody to a yet to be determined common RBC antigen was suspected. Due to the severity of clinical signs and anemia, the dog was still transfused with fresh whole blood from the "universal donor" (DEA 4 positive only). Some clinical improvement was observed within a day, but the PCV did not rise. Since the diagnosis of PK deficiency was not yet confirmed and despite the negative Coombs' test, the dog was also treated with prednisone (2 mg/kg, PO, daily). However, the anemia did not improve, and the animal's overall condition deteriorated to the point where the owners elected euthanasia. Permission to perform a necropsy was not received.

The diagnosis of PK deficiency was suspected in the WHWT described here, because of the breed, young age of anemia, persistence of the highly regenerative anemia and osteosclerosis and was confirmed by a simple DNA mutation test.

Table 1. Course of hematological parameters of a PK-deficient WHWT 4-20 month of age. Valores de los parámetros hematológicos de un paciente WHWT pK deficiente entre los 4 a 20 meses de edad.

Parameter	Units	Age (months)								Reference interval (Rizzi <i>et al</i> 2010)
		4	10	13	15	16	18	19	20	
RBC	$\times 10^6/\mu\text{L}$	1.79	2.42	1.6	1.42	2.11	1.29	0.95	0.67	5.5-8.5
PCV	%	17	23	19	13	14	9	10	9	37-55
Hb	g/dL	5.03	6.8	5.8	4.2	4.72	2.56	3.75	2.3	12-18
MCV	fL	94.97	95.04	118.75	91.54	66.35	69.76	105.26	134.32	60-77
MCHC	%	29.58	29.56	30.52	32.31	33.71	28.44	37.5	25.55	32-36
Absolute reticulocytes	μL	nd	113,498	159,840	402,286	949,500	683,700	210,330	142,040	< 70,000
Uncorrected reticulocytes	%	nd	4.69	9.99	28.33	45	53	22.14	21.2	
Corrected reticulocytes	%	nd	2.4	4.22	8.2	14	10.6	4.92	4.24	0-1.5
nRBC/100 WBC		16	0	10	0	28	12	33	28	
RPI**	Nd	Nd	1.2	2.11	3.28	5.6	4.24	1.97	1.69	**
WBC*	μL	40,000	22,900	11,300	9,600	6,700	5,800	5,500	5,000	6,000-17,000
TP	g/L	57	nd	64	68	nd	nd	52	68	60-80
PLT	$\times 10^3/\mu\text{L}$	252	nd	380	310	207	253	52	nd	200-500

RBC: red blood cells; PCV: packed cell volume; nRBC: nucleated red blood cells; RPI: reticulocyte production index; WBC: White blood cells; leukocytes; PLT: platelets; TP: total plasma proteins; nd: not determined. * Values for WBC were corrected according to the number of nRBC; ** A RPI > 2.0 is indicative of an adequate regenerative response (Torrance 2000).




Figure 2. Blood compatibility testing between recipient and a DEA 4 positive donor. Note the macroscopic incompatibility (4+) evidenced by agglutination in the major crossmatch tube.

Prueba de compatibilidad sanguínea entre el receptor y el donador positivo DEA 4. Se aprecia la incompatibilidad macroscópica (4+) evidenciada por la aglutinación en el tubo principal de reacción cruzada.

Due to the postnatal development of the RBC metabolism, the clinical signs of PK deficiency in dogs are not detected until approximately 4 months of age, as seen in this puppy. Indeed, many PK-deficient dogs are not diagnosed until one to several years of age, as the animals can often adapt well to the severe chronic anemia. Affected dogs may be first discovered only because of very pale mucous membranes on routine examination. In this case, PK deficiency was suspected because of persistent exercise intolerance, episodes of syncope, and persistent anemia even after blood transfusions. The illness may also become evident during a crisis triggered by a concurrent illness, such as an infection or toxicity, or stressful situation including strenuous exercise. The leukopenia and thrombocytopenia in the WHWT described here is not typical of PK deficiency and may indicate a secondary illness affecting the bone marrow. Also, the patient was treated for secondary diseases such as giardiasis and babesiosis, without clinical response.

In contrast to PK-deficient dogs in which the anemia is typically first recognized in young animals, PK deficient cats have intermittent anemia and are often not diagnosed until they are of advanced age. Cats exhibit

intermittent lethargy, pale mucous membranes and have intermittently mild to moderately severe anemia which may be complicated by bilirubin bile calculi (Giger 2001, Harvey *et al* 2007, Kohn and Fumi 2008, Van Geffen *et al* 2008, Giger 2010).

Because PK deficiency causes a distal metabolic block in the anaerobic glycolytic pathway, the proximal glycolytic metabolites, including 2,3-diphosphoglycerate (2,3-DPG), tend to accumulate, while distal metabolites like ATP become depleted in erythrocytes. The high erythrocytic content of 2,3-DPG facilitates the easy release of oxygen from hemoglobin by the lower hemoglobin-oxygen affinity, which in turn improves oxygen delivery and enhances tissue oxygenation, thereby ameliorating the clinical signs of the severe anemia. Indeed, this likely explains why most PK-deficient dogs can cope so well, despite a persistently severe anemia (Chapman and Giger 1990, Giger and Noble 1991, Giger 2010).

For yet unexplained reasons, all PK-deficient dogs develop a progressive myelofibrosis and then osteosclerosis, as seen in this case, though PK-deficient cats and humans do not experience osteoclerosis. However, the increased iron uptake due to hemolytic anemia caused by PK-deficiency is common to all species and can lead to hemosiderosis and eventually hemochromatosis, particularly after patients are transfused (large iron source) (Schaer *et al* 1992). Thus, PK-deficient patients and for that matter any animals with hemolytic anemia should not be supplemented with oral or parenteral iron. This was unfortunately done in this case, which emphasizes the importance of classifying the regenerative anemia into hemolytic versus blood loss anemia and reaching a definitive diagnosis. Affected WHWTs die between one and nine years of age due to anemia and/or hepatic failure (Chapman and Giger 1990, Skelly *et al* 1999, Harvey 2006, Pissard *et al* 2007, Giger 2010).

Many animals with hemolytic anemia are initially misdiagnosed and treated for infectious diseases (e.g. babesiosis in dog or mycoplasmosis infections in cats) or immune-mediated hemolytic anemia. Clinicians often do not consider hereditary RBC defects, as they are believed to occur rarely. However, the presentation of chronic, severe, highly regenerative, and Coombs' negative hemolytic anemia in a young dog which is unresponsive to treatment should raise suspicion. Moreover, in certain breeds, PK deficiency, just like other hereditary disorders and genetic predispositions to disease, may occur commonly due to the breeding of carrier animals (Harvey 2006, Sewell *et al* 2007, Giger 2010).

While in the past PK-deficiency was diagnosed by erythrocytic enzymatic activity test, assessment of oxygen-hemoglobin dissociation curve, and level of intermediates of the glycolytic pathway, such as 2,3-DPG, a definitive diagnosis in this case was established simply with the PCR mutation-specific test. This test requires only a small amount of EDTA blood or a cheek swab/brush, and can be

performed from birth (fasting for a couple of hours before brushing, prior to or 2 weeks after transfusion).

The first report of a PK-deficient WHWT dog was in 1990, in the United States. Many other cases have since been reported in WHWT dogs in the United States and other countries (PennGen data), but this is the first case in Brazil. Unfortunately, no information of the breeder or related dogs was available to further trace this dog's ancestors and to identify related potential carrier or affected dogs. Because of the international movement of purebred dog it is likely that this PK-deficient WHWT originated from the United States or England, where affected and many carrier animals have been identified (Chapman and Giger 1990, Skelly *et al* 1999, Giger 2005, Giger 2010, PennGen data).

Different causative PK mutations have been identified in different breeds such as Basenjis, Beagles, WHWT, while within a breed all affected dogs have the same mutation. Mutation-specific genetic tests permit the identification of homozygous and carrier dogs. For all the other canine breeds, detailed enzymatic activity tests that include the characterization of the isoenzymes or heat-lability are necessary. A single mutation has been identified in Abyssinian, Somali and Domestic Shorthair cats (Whitney and Lothrop 1995, Giger *et al* 1997, Skelly *et al* 1999, Giger 2005, Giger 2010).

Dogs with PK deficiency present with a severely regenerative hemolytic anemia, with PCV varying from 10 to 28%. The anemia is macrocytic and hypochromic (MCV 86 to 105 fL, and MCHC 25 to 32 g/dL), and highly regenerative (absolute reticulocyte counts and uncorrected reticulocyte counts vary from 0.5 to 1.5 x10⁶/μL and 12 to 66%, respectively). In addition, normoblasts are released into the circulation. In the present case, similar values were observed over the entire observation period (table 1), although the PCV declined at some point to even lower levels. It should be noted that the fall in PCV observed in the last month of life was associated with a diminished bone marrow response, as shown by both the lower absolute reticulocyte count and reticulocyte production index. As there was also a decline in platelet and leukocyte counts, a hematopoietic failure for other reasons than PK-deficiency may have been present. The degree of osteosclerosis was radiographically mild, but the marrow was not histopathologically examined. Osteosclerosis becomes more evident as PK-deficient dogs age (Chapman and Giger 1990, Harvey 2006).

Dogs with PK deficiency often have normal white blood cell counts. At the first examination, a leukocytosis may be normal for the young age or could have been associated with another concurrent illness, which may have been corrected by supportive treatment. Usually the dogs that live longer develop severe liver disease with hemosiderosis. In this report, the dog did not show any hepatosplenomegaly, hepatic disease or iron accumulation, but a hepatic biopsy and iron assessment were not carried

out. While PK-deficient cats and humans may also develop bilirubin calculi and gall bladder blockade, this has not been reported in PK-deficient dogs. Radiographs from this WHWT terrier described here revealed only a mildly decreased bone radiopacity of the pelvic bones, probably due to the young age of the animal (Chapman and Giger 1990, Harvey *et al* 2007, Van Geffen *et al* 2008).

No clinically practical specific treatment has yet been established for PK-deficient animals. However, experimentally successful bone marrow transplantation from compatible donors has been described in dogs and gene therapy has been attempted. In veterinary clinics, it is more important to recognize PK deficiency in order to avoid excessive diagnostic procedures for the affected dogs and unnecessary or even harmful treatments with medications such as immunosuppressive agents and iron supplementation. The treatment is mostly supportive and any other illnesses, stress or excessive exercise should be avoided. Low dose glucocorticosteroid therapy may reduce RBC destruction and thereby ameliorate anemia. The splenomegaly seen in this case could be explained because the spleen is the major site of RBC destruction, and thus splenectomy may slow the premature elimination of PK-deficient RBCs. In humans, splenectomy can reduce the degree of hemolysis in some patients, but PK-deficient Basenji dogs did not improve clinically after surgery. Thus, splenectomy may only be considered as a last resort in dogs that are persistently severely anemic or have frequently severe crises and are transfusion dependent. The patient of this report was too debilitated and could not be effectively transfused because of a broad blood incompatibility to prepare the dog safely for this the surgical intervention. As noted in this case, transient improvements and clinical stabilization can be observed. While the patient was undergoing treatment, there was apparently slight clinical improvement, but hematological parameters never returned to normal range (Weiden *et al* 1981, Giger and Noble 1991, Giger 2010).

Blood transfusions from compatible donors are sometimes needed when the anemia becomes most severe and the PK-deficient animal shows major clinical signs. Unless a hemolytic crisis develops, transfusions are rarely needed in PK-deficient dogs and cats, as they adapt quite well and can live in good health as house pets, sometimes for years without treatment. In fact, considering the high mortality rate of dogs with immune-mediated hemolytic anemia, PK deficiency may offer a better prognosis. Unfortunately, the WHWT of this report died at < 2 years of age, possibly due to concurrent illness which worsened the anemia (Chapman and Giger 1990, Giger 2005, Day 2010, Giger 2010).

In the case described here, the dog was severally anemic and symptomatic, and thus had been repeatedly transfused. Unfortunately, the dog became incompatible even to a “universal donor” and its littermates, and thus must have developed an alloantibody against a yet to be

identified common red cell antigen. While dogs do not generally have any clinically relevant naturally occurring alloantibodies, they can develop antibodies against blood groups and a common red cell antigen following transfusion, as seen in this case. An explanation for this blood incompatibility could be the presence of some other RBC antigen that could not be identified by currently used methods of canine blood typing such as the Dal antigen. In this case, the patient could be negative for *Dal* or another antigen. Nevertheless, a transfusion was deemed so desperately needed that blood from a “universal donor” was given. Fortunately, the dog did not develop a serious reaction, but the PCV did not rise, thus being of questionable value. Indeed, dogs can become sensitized to other RBC antigens than one can test for and thus be incompatible to even the “universal donor” (Callan *et al* 1995, Blais *et al* 2007, Kessler *et al* 2010).

PK deficiency is a hereditary disorder which has been studied by hematologists and geneticists for decades, in an attempt to better understand its disease process and prevalence, and in order to reach more reliable diagnosis and develop better therapeutics for affected patients. These studies have and will bring benefits for humans and for animals. Biochemical and molecular genetic tests have been developed for many diseases; however, their application as diagnostic tools for companion animals is still limited. Since this is the first case report of PK-deficiency from Brazil, it will be important to investigate the presence of asymptomatic carriers to avoid the spreading of this disorder (Giger 2010).

In this case report, we conclude that the prognosis would have been better if the etiology of severe anemia was identified soon. It is important that hereditary RBC defects, such as PK deficiency, are being considered in cases of hemolytic anemias. The approach should be fast so that we can offer a better survival for these patients. Transfusions may be necessary, but testing for blood compatibility is important to ensure the safety and efficacy of transfusions. In order to prevent the further spread of this and other hereditary diseases, it is essential to recognize not only the affected animals, but also the carriers that can transmit the mutant allele to their offspring.

ACKNOWLEDGEMENTS

The authors thank the owners of the patient reported in this study case for their patience and care.

SUMMARY

Inherited erythrocytic pyruvate kinase (PK) deficiency is an autosomal recessive hemolytic disorder described in dogs and cats. Pyruvate kinase is one of two key-regulatory enzymes in the anaerobic glycolytic pathway, and its deficiency causes premature destruction of the ATP-depleted red cells. This case study reports the clinical and laboratory findings in a West Highland White Terrier (WHWT) dog with a life-long history of weakness and exercise intolerance from Brazil. The dog was found to have

persistently profound pallor, a highly regenerative hemolytic anemia and osteosclerosis. PK deficiency was confirmed by a breed-specific DNA test for the previously described 6 bp insertion at 3' end of exon 10 in red blood cell (RBC) R- PK gene sequence. The dog was euthanized at 20 months of age due to the deterioration of its clinical condition including anemia and blood incompatibility. Other PK-deficient WHWTs have lived as long as 9 years. Hereditary red cell defects are important differential diagnoses for chronic hemolytic anemias in younger animals after excluding immune-mediated and infectious causes. Furthermore, purebred dogs for which DNA tests for hereditary diseases are available should be screened prior to breeding in order to limit the spread of the mutant allele and to avoid future production of PK-deficient animals.

REFERENCES

- Blais MC, L Berman, DA Oakley, U Giger. 2007. Canine dal blood type: a red cell antigen lacking in some Dalmatians. *J Vet Intern Med* 21, 281-286.
- Callan MB, LT Jones, U Giger. 1995. Hemolytic transfusion reactions in a dog with an alloantibody to a common antigen. *J Vet Intern Med* 9, 277-279.
- Chapman BL, U Giger. 1990. Inherited erythrocyte pyruvate kinase deficiency in the West Highland White terrier. *J Small Anim Pract* 31, 610-616.
- Clavero S, DF Bishop, ME Haskins, U Giger, R Kauppinen, RJ Desnick. 2010^a. Feline acute intermittent porphyria: a phenocopy masquerading as an erythropoietic porphyria due to dominant and recessive hydroxymethylbilan synthase mutations. *Hum Mol Genet* 19, 584-596.
- Clavero S, DF Bishop, U Giger, ME Haskins, RJ Desnick. 2010^b. Feline congenital erythropoietic porphyria: Two homozygous UROS missense mutations cause the enzyme deficiency and porphyrin accumulation. *Mol Med* 16, 381-388.
- Day MJ. 2010. Immune-Mediated Anemias in the Dog. In: Weiss DJ, Wardrop KJ (eds). *Schalm's Veterinary Hematology*. 6th ed. Blackwell Publishing Ltd, Ames, USA, Pp 216-225.
- Giger U, NA Noble. 1991. Determination of erythrocyte pyruvate kinase deficiency in Basenjis with chronic hemolytic anemia. *J Am Vet Med Assoc* 198, 1755-1761.
- Giger U, GD Mason, P Wang. 1991. Inherited erythrocyte pyruvate kinase deficiency in a Beagle. *Vet Clin Pathol* 20, 83-86.
- Giger U, Y Rajpurohit, P Wang, S Ford, B Kohn, A Niggemeier, DF Patterson, E Beutler, PS Henthorn. 1997. Molecular basis of erythrocyte pyruvate kinase (R-PK) deficiency in cats. *Blood* 90, 2701.
- Giger U. 2001. Hereditary erythrocyte disorders. In: August JR (ed). *Consultations of Feline Med Surg*. 4th ed. W B Saunders, Philadelphia, USA, Pp 484-489.
- Giger U. 2005. Regenerative anemias caused by blood loss or hemolysis. In: Ettinger SJ, Feldman EC (eds). *Textbook of Veterinary Internal Medicine: Diseases of Dog and Cat*. W B Saunders, Philadelphia, USA, Pp 1886-1907.
- Giger U, DR Sargan, EA McNiel. 2006. Breed-specific hereditary diseases and genetic screening. In: Ostrander EA, Giger U, Lindblad-Toh K (eds). *The Dog and Its Genome*. Cold Spring Harbor Laboratory Press, New York, USA, Pp 249-290.
- Giger U. 2010. Hereditary Erythrocyte Enzyme Abnormalities. In: Weiss DJ, Wardrop KJ (eds). *Schalm's Veterinary Hematology*. 6th ed. Blackwell Publishing Ltd, Ames, USA, Pp 179-186.
- Harvey JW, RR King, CR Berry, JT Blue. 1991. Methaemoglobin reductase deficiency in dogs. *Comp Haem Intern* 1, 55-59.
- Harvey JW. 2006. Pathogenesis, laboratory diagnosis, and clinical implications of erythrocyte enzyme deficiencies in dogs, cats, and horses. *Vet Clin Pathol* 35, 144-156.
- Harvey AM, PE Holt, FJ Barr, F Rizzo, S Tasker. 2007. Treatment and long-term follow-up of extrahepatic biliary obstruction with bilirubin cholelithiasis in a Somali cat with pyruvate kinase deficiency: Case Report. *J Feline Med Surg* 9, 424-431.
- Harvey JW. 2010. Erythrocyte biochemistry. In: Weiss DJ, Wardrop KJ (eds). *Schalm's Veterinary Hematology*. 6th ed. Blackwell Publishing Ltd., Ames, USA, Pp 131-135.
- Kessler RJ, J Reese, D Chang, M Seth, AS Hale, U Giger. 2010. Dog erythrocyte antigens 1.1, 1.2, 3, 4, 7 and Dal blood typing and cross-matching by gel column technique. *Vet Clin Pathol* 39, 306-316.
- Kohn B, R Freistedt, A Pekrun, P Wang, U Giger. 1999. Chronische hämolytische Anämie und Osteosklerose aufgrund einer Erythrozyten-Pyruvatkinase-Defizienz bei einem Langhaardackel. *Kleintierpraxis* 44, 437-445.
- Kohn B, C Fumi. 2008. Clinical course of pyruvate kinase deficiency in Abyssinian and Somali cats. *J Feline Med Surg* 10, 145-153.
- Pissard S, M de Montalembert, D Bachir, I Max-Audit, M Goossens, H Wajcman, B Bader-Meunier. 2007. Pyruvate kinase (PK) deficiency in newborns: the pitfalls of diagnosis. *J Pediatr* 150, 443-445.
- Rizzi TE, JH Meinkoth, KD Clinkenbeard. 2010. Normal Hematology of the Dog. In: Weiss DJ, Wardrop KJ (eds). *Schalm's Veterinary Hematology*. 6th ed. Blackwell Publishing Ltd., Ames, USA, Pp 799-810.
- Schaer M, JW Harvey, M Calderwood-Mays, U Giger. 1992. Pyruvate kinase deficiency causing hemolytic anemia with secondary hemochromatosis in Cairn terrier. *J Am Anim Hosp Assoc* 28, 233-239.
- Sewell AC, ME Haskins, U Giger. 2007. Inherited metabolic disease in companion animals: searching for nature's mistakes. *Vet J* 174, 252-259.
- Skelly BJ, M Wallace, YR Rajpurohit, P Wang, U Giger. 1999. Identification of a 6 base pair insertion in West Highland White Terriers with erythrocyte pyruvate kinase deficiency. *Am J Vet Res* 60, 1169-1172.
- Torrance A. 2000. Overview of Haematological Diagnostic Techniques. In: Day M, Mackin A, Littlewood J (eds). *Manual of Canine and Feline Haematology and Transfusion Medicine*. BSAVA, Gloucester, UK, Pp 3-17.
- Van Geffen C, K Savary-Bataille, K Chiers, U Giger, S Daminet. 2008. Bilirubin cholelithiasis and haemosiderosis in an anaemic pyruvate kinase-deficient Somali cat. *J Small Anim Pract* 49, 479-482.
- Weiden PL, RC Hackman, HJ Deeg, TC Graham, ED Thomas, R Storb. 1981. Long-term survival and reversal of iron overload after marrow transplantation in dogs with congenital hemolytic anemia. *Blood* 57, 66-70.
- Whitney KM, CD Lothrop Jr. 1995. Genetic test for pyruvate kinase deficiency of Basenjis. *J Am Vet Med Assoc* 207, 918-921.